



DOWN BUT NOT OUT -


New Thoughts on Canine Disc Disease

Henry is a 5-year-old male Dachshund that presented at Colorado Canine Orthopedics with hind limb paralysis. Henry had been slightly ataxic 2 days prior to presentation and was treated by his referring veterinarian with oral prednisone. Henry improved to the point of being able to run and jump within 24 hours, but by 36 hours showed signs of complete paralysis.

At the time of initial presentation Henry was normal in the front legs but had no motor function in either rear limb. Patellar and withdrawal reflexes were exaggerated and deep and superficial pain sensation was absent in both hind limbs. Hyperpathia was present in the T-L region of the back and the panniculus cut-off was also in the T-L region.

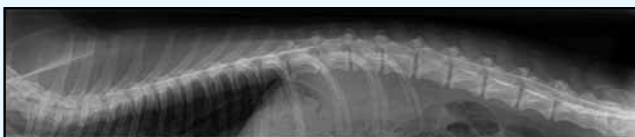
Plain film radiographs and a myelogram were performed under general anesthesia and revealed a narrowed disc space at T13-L1 and spinal cord swelling and compression in the same location (**Figures 1 & 2**).

Continued Inside...



5520 North Nevada • Suite 100 • Colorado Springs • Colorado 80918

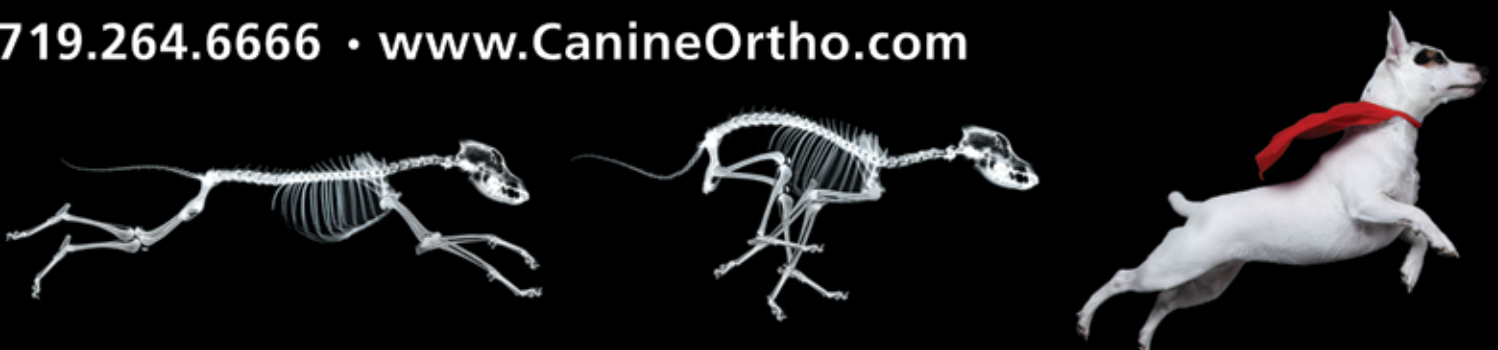PRSR STD
US POSTAGE
PAID
COLO SPGS, CO
PERMIT NO 434



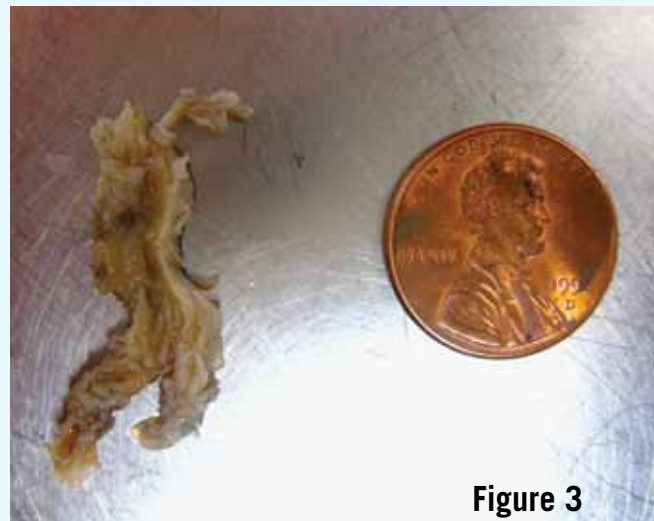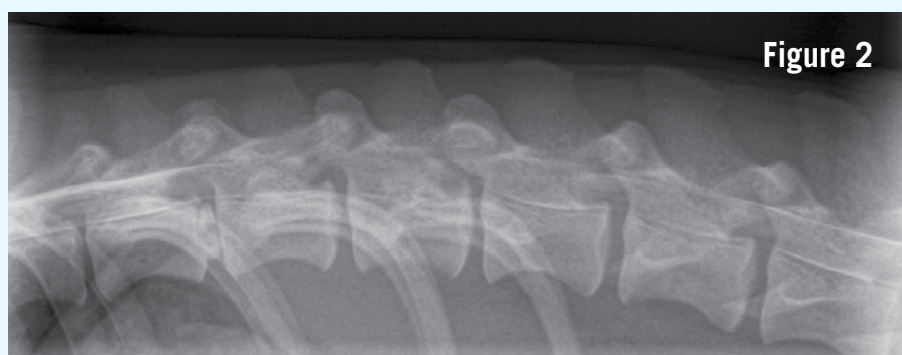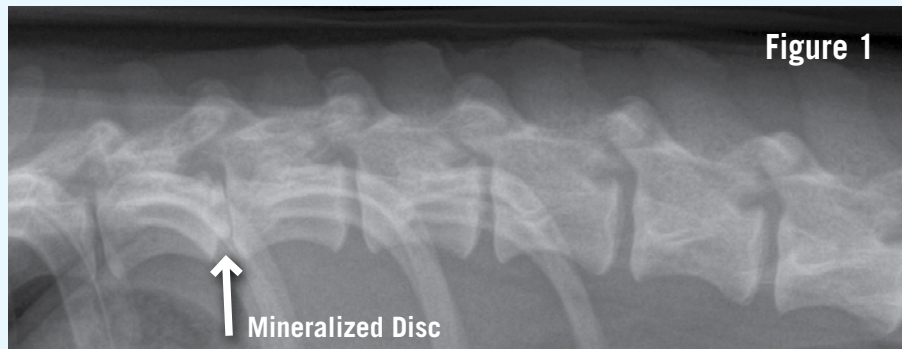
**DOWN BUT NOT OUT -
New Thoughts on Canine Disc Disease**

COLORADO CANINE ORTHOPEDICS

719.264.6666 • www.CanineOrtho.com



Continued... **DOWN BUT NOT OUT - NEW THOUGHTS ON CANINE DISC DISEASE**



It is interesting to note a mineralized disc was obvious at T11-12 but had not herniated. Henry was taken to surgery and a left hemilaminectomy was performed. A large amount of disc material was found and removed from within the spinal canal (**Figure 3**). Three and one half mg of duramorph was instilled at the surgery site and the site was closed routinely. Henry spent the night in ICU on a constant rate infusion of fentanyl.

Henry was discharged from the hospital and the owners were instructed how to express the urinary bladder. At the time of suture removal, fourteen days after surgery, Henry had regained superficial and deep pain sensation and a minimal amount of hind limb and tail motor function. Four weeks after surgery Henry was fully ambulatory but still had mild neurologic deficits.

Henry's case illustrates numerous important facts and points regarding canine thoracolumbar (T-L) intervertebral disc disease (IVDD). Henry's initial treatment involved the use of corticosteroids, which may have been successful right up until the moment they may have lead to his demise.

The use of corticosteroids has been shown to effectively decrease inflammation and thereby decrease ménage and discogenic pain. Corticosteroids have also been shown to lessen the effects of severe spinal cord trauma. In this instance, prednisone probably decreased pain, which lead to increased activity and may have contributed to the ensuing paralysis.

Corticosteroids do have a place in the management of IVDD. Most surgeons administer 30 mg/kg of Solumedrol prior to myelography and surgery. Studies suggest the detrimental effects of trauma on the spinal cord are mitigated if steroids are on board prior to the trauma and nearly as effective if administered within eight hours. Corticosteroids can also make patients with non-surgical

IVDD more comfortable, but should always be used in conjunction with CAGE REST.

In this case the decision to perform decompressive surgery was black and white. In our opinion (shared by most surgeons and neurologists) non-ambulatory dogs with a tentative diagnosis of T-L IVDD should be decompressed as soon as possible. Walking dogs, with minimal neurological deficits should be treated with cage rest unless they are clearly worsening or recurrent.

The neurologic examination revealed normal front limbs and intact hind limb reflexes placing the lesion between T-3 and L-3. Plain radiographs were suggestive of a T13-L1 disc herniation but myelography, CT or MRI are required for a more precise localization. In our experience, myelography is accurate in nearly all small breed dogs with T-L IVDD.

The fact Henry was deep pain negative prior to surgery but still recovered, is not surprising. Recent studies suggest T-L IVDD resulting in the loss of deep pain may yield up to a 69% success rate with surgery. Unless patients have been deep pain negative for an extended period (a week or longer) we recommend surgical decompression. The time it took Henry to regain pain sensation (present at suture removal) and motor function (about 4 weeks) is typical although some dogs will recover more rapidly and some more slowly. Dogs that do not regain deep pain sensation by 4 weeks have a poor prognosis for return of voluntary motor function but may do quite well in a cart. The likelihood of IVDD recurrence in dogs that have undergone surgery is between five and ten percent.

If you have questions about a spinal or orthopedic case please do not hesitate to call.

Colorado Canine Orthopedics (719) 264-6666